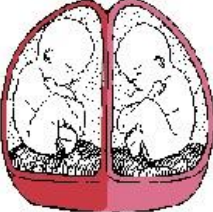
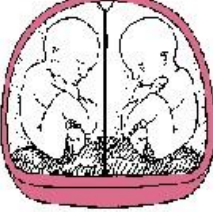



perinatology.com: You've Got Twins!

A twin pregnancy most commonly occurs when two separate eggs are fertilized by separate sperm to form two babies that develop separately. These are commonly called fraternal twins. Each twin is surrounded by an outer membrane called the chorion that forms the placenta, and an inner membrane called the amnion that forms the amniotic sac (bag of waters). Because there are two placentas (dichorionic) and two amniotic sacs (diamniotic) the twins are called dichorionic diamniotic twins. Twins may also occur if a single fertilized egg divides to form two separate babies. These twins are referred to as "identical" twins. Depending on how soon after conception the fertilized egg divides each twin may develop its own placenta and amniotic sac (dichorionic diamniotic), the twins may share one placenta (monochorionic) and develop in two separate amniotic sacs (diamniotic), or the twins may share one placenta (monochorionic) and share one amniotic sac (monoamniotic).

Women carrying twin pregnancies are more likely to have preterm labor, small babies, a baby with a birth defect, preeclampsia, premature rupture of their membranes, gestational diabetes, and cesarean delivery. In addition identical twins are at increased risk for birth defects involving the brain and heart. Identical twins that share a placenta (monochorionic) may develop twin-to-twin transfusion syndrome (TTTS) or twin anemia-polycythemia sequence (TAPS). In addition, identical twins that also share the same amniotic sac are at risk for becoming entangled in each other's umbilical cord. Because of the different problems that may occur with twins that share a placenta or an amniotic sac the recommendations for monitoring and delivery of these different types of twin pregnancies are also different. It is important to identify the number of placentas and amniotic sacs as accurately as possible. **The accuracy in identifying a twin pregnancy as monochorionic or dichorionic is highest when the ultrasound is performed before 14 weeks.**

	<p><u>Dichorionic diamniotic (Di Di)</u> Ultrasound findings Two chorions (placentas), two amniotic sacs, two yolk sacs. Lambda or "twin peak" sign (a triangular shape where each set of membranes meets) The lambda sign becomes difficult to identify after 20 weeks Complications : Fetal growth restriction, preeclampsia, premature rupture of their membranes, preterm labor, gestational diabetes, abruption, pyelonephritis, PUPPs, thromboembolism, acute fatty liver, cesarean delivery, and postpartum hemorrhage. Evaluation of growth Every 4 weeks Antenatal testing : Starting 36 0/7 weeks or sooner in all situations in which surveillance would ordinarily be performed in a singleton pregnancy Delivery 38 weeks</p>
	<p><u>Monochorionic diamniotic (Mo Di)</u> Ultrasound findings One chorion (placenta), two amniotic sacs, two yolk sacs. T-shape where the membranes meet Complications In addition to the complications seen with DiDi twins MoDi twins are at increase risk for neural tube and heart defects, symmelia, extrophy of the cloaca, twin reversed arterial perfusion sequence (TRAP sequence), twin-to-twin transfusion syndrome (TTTS), and twin anemiapolycthemia sequence (TAPS) Evaluation of growth : Every 3 to 4 weeks, Evaluation for twin-to twin transfusion: Every 2 weeks. Antenatal testing: Starting at 32 0/7 weeks or sooner in all situations in which surveillance would ordinarily be performed in a singleton pregnancy Delivery 34 to 37 weeks</p>
	<p><u>Monochorionic monoamniotic (Mo Mo)</u> Ultrasound findings One chorion (placenta), one amniotic sac one or two yolk sacs. No membrane. No T sign or lambda sign Complications In addition to the complications seen with MoDi twins MoMo twins are at increased risk for cord entanglement with an increased risk for stillbirth Evaluation of growth every 3 to 4 weeks Antenatal testing Individualized Delivery 32 to 34 w <small>LifeART image copyright 2005 Lippincott Williams & Wilkins. All rights reserved.</small></p>

During an ultrasound examination about 70 to 80% of all twins will be expected to have two separate placentas. About 20 to 30% of twins would be expected to share one placenta and have separate amniotic sacs. A very small number of twins (~1%) would be expected to share one placenta and be in the same amniotic sac. 5.4% of twins resulting from assisted reproductive technology may be expected to be monochorionic. 3% of monochorionic placentas may have two lobes and appear to be dichorionic